Statement Submitted for Oral Presentation by:

Marsha Kay, M.D. Chair Pediatric Gastroenterology
Director Pediatric Endoscopy, Cleveland Clinic Children's
Cleveland, Ohio

Consumer Public Safety Commission
Public Hearing on Notice of Proposed Rulemaking
October 22, 2013
Safety Standards for High-Powered Magnet Sets

Good morning. I am Dr. Marsha Kay, chair of the Department of Pediatric Gastroenterology and Nutrition and Director of Pediatric Endoscopy at Cleveland Clinic Children's in Cleveland, Ohio. I am also a member of the North American Society for Pediatric Gastroenterology, Hepatology and Nutrition (NASPGHAN).

I first want to thank the Consumer Product Safety Commission for holding today's hearing and for providing me the opportunity to talk about the dangers that high-powered, or neodymium, magnets pose to children. In the interest of time, I will focus my remarks on the types and severity of injuries that result from ingestion of high-powered magnets and why there is a high likelihood of injury upon ingestion.

Difficulty of Magnet Ingestion Diagnosis

As a physician who is experienced in the removal of ingested foreign bodies, I want to emphasize that high-powered magnet ingestion is different than other ingested foreign bodies. Because of their small size and smooth surface, ingestion of magnets may cause no immediate symptoms. Consequently, there can be marked delay in diagnosis and treatment. Unless the ingestion is witnessed by an adult, which is not typically the case, early diagnosis is complicated by the often inability of a toddler, young child, or a child or adolescent with a developmental disorder to verbalize that an ingestion has occurred.

Injury from magnet ingestion occurs almost immediately, but initial symptoms are not unique to magnet ingestion making diagnosis difficult. First symptoms, such as abdominal pain from bowel trapped between magnets, may take 8-24 hours or longer to occur. Later symptoms, such as fever and vomiting, are non-specific and resemble more common ailments such as acute infection (acute gastroenteritis).

Mechanism of Bowel Wall Injury

Magnet ingestions are serious and life threatening. If more than two of these high-powered magnets are swallowed, their attractive force allows the magnets to "find" each other in the body. This can occur across or between different segments of the bowel. For example, connections can occur between the stomach and the small intestine, between the small intestine and the colon, or sometimes across loops of bowel. (Figure 1) Although the tissue of the intestinal tract is tough, it's no match for these magnets. Once magnetically attached across the bowel wall, they do not break apart, which can cause severe injury.

Deep pressure ulceration can occur within eight hours or less following ingestion. If left untreated, this can lead to bowel wall perforation, which represents a serious and immediate risk to the patient. The leaking of intestinal contents into the abdominal cavity rapidly results in infection and peritonitis, which is inflammation of the tissue that covers the intestine and internal organs.

Fistulization (e.g., gastro-enteric, entero-enteric, etc.) or development of connections between two bowel segments not normally connected caused by high-powered magnet ingestion has been reported frequently.

In rare cases, ingested magnets may attract across several loops of intestine causing the bowels to twist, or volvulize. The twisted loop of bowel obstructs the flow of intestinal contents and blood flow, leading to lack of oxygen to the bowel wall and resultant ischemia. This is a surgical emergency requiring immediate operation. Delay in treatment can lead to the need for resecting necrotic, or dead, bowel. If too much bowel is removed, "short bowel syndrome" may be the result, requiring life-long intravenous nutrition (total parenteral nutrition, also known as TPN) or potentially even a small bowel transplant.

At my institution, due to delay between time of ingestion and the family recognizing the need to seek medical attention, most patients with

magnet ingestion have required surgery as a result of subsequent complications, including bowel obstruction and/or fistulization between loops of bowel.

Conclusion

There is a spectrum of diagnosis, symptoms, treatment and injury following ingestion.

If ingestion is recognized, it may be acted upon in timely way, including through endoscopic removal and/or surgical intervention. However, even with a known ingestion, there may be a delay in recognition of the seriousness of ingestion by either the family or health care provider.

Other cases may be unrecognized until significant consequences occur. In the best case this may yield a stable patient for whom surgery is required, which may include bowel resection. In the worst case this may include an unstable patient secondary to intestinal perforation who may be septic, require admission or transfer to a pediatric intensive care unit, and one or more bowel resections. If the patient survives the episode, significant consequences are possible, including the need for additional surgery. If the bowel is necrotic and needs to be removed the patient may develop "short gut syndrome." Over the long term the patient may require multiple hospitalizations due to complications. In addition following peritonitis there may be long term fertility issues, especially in females, analogous to perforated appendicitis.

These magnet ingestions unfortunately continue to occur and patients are cared for at our hospital and medical institutions throughout the country. Despite educational efforts by both the NASPGHAN, the American Academy of Pediatrics, patient and consumer organizations and the media, there remains a lack of awareness by the lay public, primary care providers and emergency room personnel as to the potential consequences of these types of ingestions and the correct management algorithms to be followed for management of magnet ingestion.

Additionally, because patients may be initially asymptomatic, the need for urgent evaluation, as well as therapy, may not be appreciated resulting in potentially devastating consequences for the patient as outlined above.

For these reasons, I strongly support and ask the Commission to finalize its proposed magnet safety standards.

Thank you.
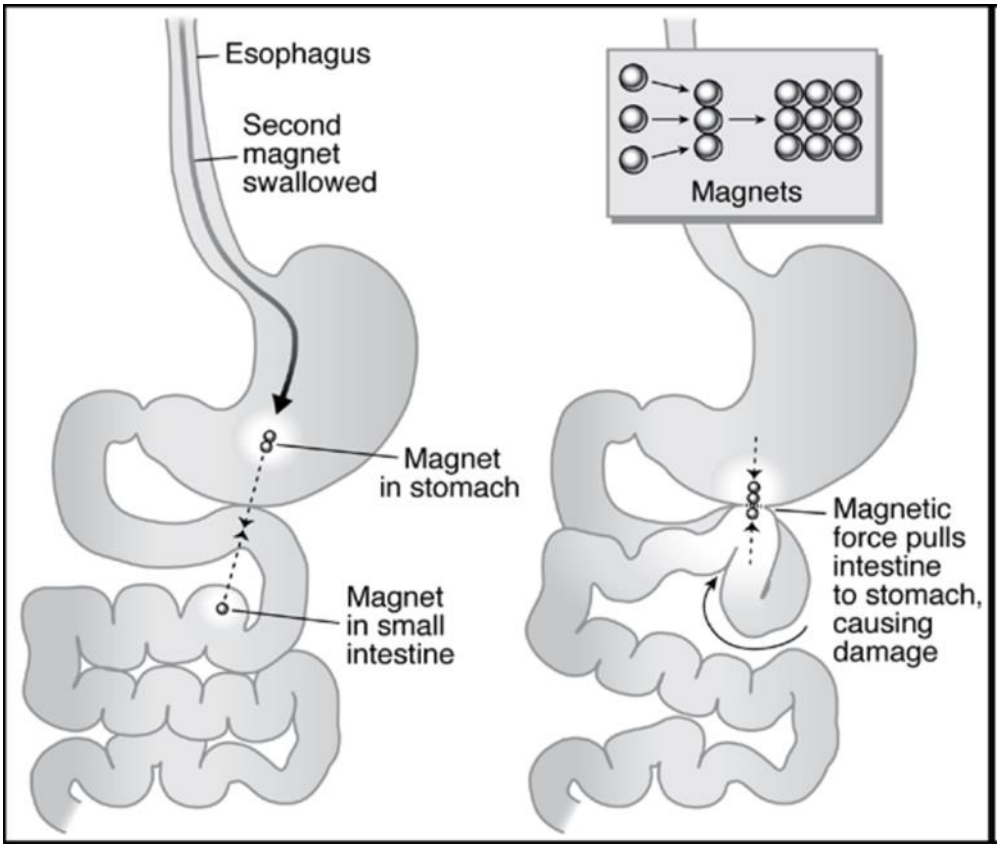
Figure 1.